



Use of topical mineral powder as monotherapy for treatment of active peptic ulcer bleeding CME

Joseph J. Y. Sung, MD, PhD,¹ Sulleman Moreea, FRCP,² Harinder Dhaliwal, MD,³ Dana C. Moffatt, MD,⁴ Krish Ragunath, MD,⁵ Terry Ponich, MD,⁶ Alan N. Barkun, MD,⁷ Ernst J. Kuipers, MD, PhD,⁸ Robert Bailey, MD,⁹ Fergal Donnellan, MD,¹⁰ David Wagner, MS,¹¹ Keith Sanborn, MS,¹² James Lau, MD¹³

Singapore; Bradford, Nottingham, UK; Ottawa, London, Ontario; Winnipeg, Manitoba; Montreal, Quebec; Edmonton, Alberta; Vancouver, British Columbia, Canada; Rotterdam, The Netherlands; Winston-Salem, North Carolina; West Lafayette, Indiana, USA; Hong Kong, China

Background and Aims: The aim of this study was to evaluate the safety and effectiveness of Hemospray (Cook Medical, Winston-Salem, NC, USA), a hemostatic powder, as monotherapy for active peptic ulcer bleeding.

Methods: In this prospective, multicenter, single-arm study, patients with Forrest Ia or Ib peptic ulcers underwent endoscopic application of Hemospray as treatment of first intent. Effectiveness endpoints were successful hemostasis at the end of the index endoscopy, recurrent bleeding within 72 hours and from 72 hours to 30 days, adverse events requiring reintervention or resulting in morbidity or mortality, and 30-day mortality.

Results: Hemospray was successfully administered in 98.5% of patients (66/67). Hemostasis was achieved at the index endoscopy in 90.9% of patients (60/66) with Hemospray alone and in an additional 4 patients treated with additional modalities, yielding an overall hemostasis rate of 97.0% (64/66). Rebleeding occurred in 13.3% of patients (8/60), 5 within 72 hours and 3 between 72 hours and 30 days. Two cases of perforation and 2 patient deaths occurred during the study, but none of these cases or any other adverse events were attributed to the use of Hemospray. The rate of early rebleeding was significantly higher in patients with Forrest Ia ulcers compared with patients with Forrest Ib ulcers. Higher rates of early bleeding in patients with Forrest Ia ulcers is consistent with results from studies where Hemospray was used as rescue after failure of conventional methods.

Conclusions: Hemospray is an effective initial treatment for patients with active peptic ulcer bleeding, but care should be taken to monitor for recurrent bleeding. (Clinical trial registration number: NCT01306864.) (Gastrointest Endosc 2022;96:28-35.)

Abbreviations: HALT, Hemostasis of Active GI Luminal Tract Bleeding; UGIB, upper GI bleeding.

DISCLOSURE: The following authors disclosed financial relationships: J. Y. Sung: Editor-in-Chief of the Journal of Gastroenterology and Hepatology. K. Ragunath: Educational and research grants from Cook Medical; associate editor for Digestive Endoscopy Journal. D. Wagner: Employee of Cook Medical. K. Sanborn: Employee of Cook Research Incorporated and Cook Group Company. All other authors disclosed no financial relationships. Research support for this study was provided by Cook Medical.

See CME section, p. 139.

Copyright © 2022 by the American Society for Gastrointestinal Endoscopy. Published by Elsevier, Inc. This is an open access article under the CC BY license (<http://creativecommons.org/licenses/by/4.0/>).

0016-5107

<https://doi.org/10.1016/j.gie.2022.01.020>

Received October 28, 2021. Accepted January 26, 2022.

Current affiliations: Lee Kong Chian School of Medicine, Nanyang Technological University, Singapore (1), Department of Gastroenterology,

Bradford Teaching Hospitals Foundation Trust, Bradford, UK (2), Department of Medicine, Division of Gastroenterology, The Ottawa Hospital, Ottawa, Ontario, Canada (3), Department of Medicine, Max Rady College of Medicine, University of Manitoba, Winnipeg, Manitoba, Canada (4), Department of Gastroenterology, NIHR Nottingham Digestive Diseases Biomedical Research Centre, Queens Medical Centre, Nottingham University Hospitals NHS Trust, Nottingham, UK (5), Division of Gastroenterology, Western University, London, Ontario, Canada (6), Division of Gastroenterology, McGill University Health Centre, McGill University, Montreal, Quebec, Canada (7), Department of Gastroenterology and Hepatology, Erasmus MC University Medical Center, Rotterdam, The Netherlands (8), Department of Gastroenterology and Hepatology, Royal Alexandra Hospital, Edmonton, Alberta, Canada (9), Department of Gastroenterology, Vancouver General Hospital, Vancouver, British Columbia, Canada (10), Cook Endoscopy, Winston-Salem, North Carolina, USA (11), Cook Research Incorporated, West Lafayette, Indiana, USA (12), Department of Surgery, The Chinese University of Hong Kong, Hong Kong, China (13).

Reprint requests: Joseph Sung, MD, PhD, Nanyang Technological University, Lee Kong Chian School of Medicine, 11 Mandalay Rd, Singapore 308232.

Acute upper GI bleeding (UGIB) is a common medical condition worldwide.¹ Nonvariceal UGIB ranges in severity from temporary and self-limiting to near-fatal or fatal.² Peptic ulcer disease is the most common cause of nonvariceal UGIB and accounts for at least 50% of UGIB cases.³ UGIB is typically associated with mortality ranging from 2% to 15%;⁴ however, mortality rates of up to 27% have been reported.⁵ Endoscopic intervention is indicated for patients with an actively bleeding or spurting arterial vessel or for patients with a nonbleeding visible vessel or adherent clot at an ulcer site.^{3,6} These patients with Forrest Ia, Ib, Ila, or IIb ulcers are considered high risk for rebleeding.⁶⁻⁸

Standard endoscopic treatment modalities include injection (epinephrine solution), mechanical devices (endoscopic clips, bands), and thermal methods (electrocautery probe, heater probe, argon plasma coagulation, laser).⁹ All standard modalities are effective with 85% to 95% success rates and have been shown to maintain hemostasis, decrease rebleeding, reduce the need for surgery, and, for some patient populations, lower mortality rates when compared with medical treatment or injection alone.^{10,11} However, standard endoscopic treatment may not achieve hemostasis in 8% to 15% of patients with active peptic ulcer bleeding.¹² Rebleeding rates of 5% to 10% have been reported after initial hemostasis using combined endoscopic therapy in patients treated for acute UGIB.¹⁰ In patients with rebleeding within the first 30 days of treatment, 60% to 76% of rebleeding occurs within the first 72 hours after the procedure.¹¹

Topical hemostatic powders are an attractive treatment option for patients with peptic ulcer bleeding because they are easy to use,^{1,6,13,14} can be applied to sites that are difficult to reach with endoscope and hemostatic devices,^{1,6,13,14} can treat large areas in which the exact location of bleeding is unknown,^{1,6,14} and do not require direct contact with the bleeding site.^{6,14,15} Hemospray (Cook Medical, Winston-Salem, NC, USA), initially known as TC-325, is a topical mineral powder delivered through a catheter via the working channel of an endoscope with carbon dioxide propellant.^{10,16} In the presence of active bleeding, Hemospray forms an adherent mechanical barrier on contact to stop bleeding.^{14,17-19} Hemospray is nontoxic, is neither absorbed into nor metabolized by the body, and is eliminated from the stomach and duodenum within 72 hours of administration.¹⁶ Recent meta-analyses indicated that Hemospray is safe and effective for treating patients with bleeding from multiple causes of UGIB either alone, in combination with other therapeutic agents, or as rescue therapy after failure of standard modalities.^{20,21} The objective of this study was to evaluate the safety and effectiveness of Hemospray as a monotherapy in patients with actively bleeding peptic ulcers.

METHODS

Study design and patient enrollment

The Hemostasis of Active GI Luminal Tract Bleeding (HALT) study (clinicaltrials.gov identifier NCT01306864) was a prospective, single-arm, multicenter study sponsored by Cook Medical (Bloomington, Ind, USA). Patients with at least 1 endoscopically confirmed, actively bleeding (Forrest Ia or Ib) peptic ulcer met study inclusion criterion. Patients were excluded from enrollment if they were younger than 18 years old, pregnant or lactating, unable or unwilling to provide consent, taking a thienopyridine antiplatelet agent, or assessed with an American Society of Anesthesiologists classification of IV. Patients with suspected GI perforation, contraindications to undergo an endoscopic procedure, a surgically altered stomach (eg, bariatric surgery), an intrahepatic portosystemic shunt, a GI fistula, an international normalized ratio >2.5, and those treated with epinephrine, sclerosant injection, clips, or thermal therapy at the bleeding site before application of Hemospray were also excluded. Patients were considered enrolled in the study when written informed consent was obtained before or within 72 hours of the study procedure. Approval was obtained from the institutional review board or ethics committee at each site.

Device and procedure

All physicians who participated in this study were highly skilled endoscopists trained in the use of Hemospray as a novel technology. Upper GI endoscopy was performed on consecutive patients with symptoms consistent with UGIB. If an actively bleeding peptic ulcer was identified, the ulcer was treated with Hemospray. Any adherent clot was removed in accordance with accepted clinical practice, and management of the underlying ulcer was based on the appearance after removing the clot. Per study protocol, only Hemospray could be applied to the bleeding ulcer; no injection or other modalities were allowed before the application of Hemospray. Hemospray was not applied to nonbleeding visible vessels because the product only binds to actively bleeding ulcers.

Each device canister contained 20 g of Hemospray; up to 3 canisters could be administered to achieve initial hemostasis. Once the Hemospray was applied, patients were observed for 5 minutes, and initial hemostasis was confirmed by the absence of bleeding at the conclusion of the 5-minute observational period. If initial hemostasis was not achieved with Hemospray application(s), patients were treated with standard methods according to physician preference, and the Hemospray treatment was considered a failure. After initial hemostasis was achieved, postoperative therapy was continued according to institutional standard of care, including medications (eg, proton pump inhibitors) as needed. After a successful index procedure, patients were observed for symptoms of

recurrent bleeding, defined in the next section below. Patients with signs or symptoms of recurrent bleeding underwent repeat endoscopy at the physician's discretion. Only patients with endoscopically confirmed bleeding from the treated ulcer bed on the second endoscopy were classified with recurrent bleeding. These recurrent bleeds were treated with standard methods or Hemospray at the physician's discretion. Patient follow-up was performed by phone at 72 hours, 7 days, and 30 days postprocedure or in person if the patient was still hospitalized.

Definitions and study endpoints

Distinct ulcers with a common ulcer bed were considered a single ulcer. If a patient had multiple distinct ulcers (>4 cm apart), data on only the most severe ulcer as determined by the examining physician were collected. The primary study endpoint was the proportion of patients with visually confirmed persistent or recurrent bleeding within 72 hours of the index procedure. Persistent bleeding was defined as bleeding at the conclusion of the index endoscopy (thereby a failure to achieve initial hemostasis with Hemospray). Failure to achieve initial hemostasis was defined as persistent bleeding requiring crossover to standard modalities after administration of up to 3 Hemospray powder canisters. The primary endpoint analysis included all patients who signed an informed consent document and in whom Hemospray was applied with the intention to be used as a single modality application. Additional study outcome measures were the proportion of patients with late recurrent bleeding (between 72 hours and 30 days) and the rate of serious adverse events and mortality within 30 days of the index procedure. Adverse events that required re-intervention or resulted in patient morbidity or mortality were reported. Clinical signs and symptoms of rebleeding (ie, hematemesis, hematochezia, hemoglobin decrease, hypotension, melena, and tachycardia) were noted. Follow-up endoscopy was performed at the discretion of the physician to visually confirm an active early or late recurrent bleeding episode.

Statistical analysis

Continuous variables were assessed by mean values and standard deviations, and categorical variables were assessed as counts and percentages. The Fisher exact test was used to compare proportions. A multiple logistic regression analysis was performed to evaluate clinically relevant variables associated with persistent or recurrent bleeding, including sex, ulcer location, ulcer diameter, Forrest classification, and initial hypotension; the χ^2 test generated the *P* values for the associated logistic regression. All analyses were performed with SAS software (version 9.4; SAS Institute, Inc, Cary, NC, USA). A *P* < .05 was considered significant.

RESULTS

Sixty-seven patients were enrolled in the HALT study between December 2011 and April 2017. There were 258 screen failures because of nonbleeding ulcers at the time of endoscopy. The mean patient age was 65.7 years (range, 27-98), and 68.7% of patients were men. Nine patients (13.4%) were already hospitalized for another illness when they developed evidence of UGIB. Patient and ulcer characteristics are shown in Table 1, and Figure 1 illustrates a Forrest Ia ulcer treated with Hemospray.

Hemospray was successfully administered in 98.5% of patients (66/67). Among the 67 patients, 59 underwent a single Hemospray application and 8 underwent 2 Hemospray applications during the index procedure. A single canister of Hemospray was used in 55 patients, 2 canisters were used in 8 patients, and 3 canisters were used in 4 patients. In 1 patient, Hemospray could not be administered when 2 catheters that were separately inserted into the working channel occluded successively; therefore, the mineral powder could not be deployed. This patient was subsequently treated with standard hemostatic methods and was not included in the endpoint analyses. As a monotherapy, Hemospray achieved initial hemostasis in 90.9% of patients (60/66). Conventional endoscopic and pharmacologic treatment modalities were used for the 6 patients in whom initial hemostasis was not achieved with Hemospray. End of procedure hemostasis, with Hemospray alone or combined with other modalities, was achieved in 97.0% of patients (64/66) patients.

One patient with persistent bleeding was converted to open surgery after the first application of Hemospray. This patient subsequently died of liver failure 2 days later. The other patient with persistent bleeding after 2 applications of Hemospray was treated with proton pump inhibitor therapy without further endoscopic intervention. Additional treatment outcomes are shown in Table 2.

There were 10 events of clinical signs or symptoms of rebleeding in 9 patients. However, visually confirmed early recurrent bleeding occurred in 7.6% of patients (5/66) and late recurrent bleeding in 4.5% (3/66), resulting in an overall recurrent bleeding rate of 12.1% (8/66). For endpoint analyses, early rebleeding and 30-day mortality rates were significantly different in patients with Forrest Ia ulcers compared with patients with Forrest Ib ulcers (*P* = .03 and *P* = .026, respectively; Fisher exact test, Table 2). The association between baseline patient or ulcer characteristics and the incidence of early or late rebleeding was further assessed, where Forrest classification was the only characteristic significantly associated with early or late rebleeding (*P* = .002), with a higher likelihood of rebleeding with Forrest Ia ulcers compared with Forrest Ib ulcers (Supplementary Table 1, available online at www.giejournal.org). Multiple logistic regression analysis also indicated that Forrest

TABLE 1. Patient and ulcer characteristics

Characteristics	Value
Patient	
Age, y	65.7 ± 17.5
Median age, y (range)	67 (27-98)
Sex	
Male	68.7 (46/67)
Female	31.3 (21/67)
Hypertension	47.8 (32/67)
Diabetes	25.4 (17/67)
Hospitalized for another illness when GI bleeding occurred	13.4 (9/67)
Previous treatment(s) for peptic ulcer bleeding	
Hemostasis clips	35.7 (5/14)
Injection	42.9 (6/14)
Thermal probe	28.6 (4/14)
Upper GI surgery	0 (0/14)
Other endoscopic/surgical treatment	7.1 (1/14)
Transfusion	64.3 (9/14)
Intravenous administration of proton pump inhibitor	64.3 (9/14)
Oral administration of proton pump inhibitor	21.4 (3/14)
Other medical treatment	0 (0/14)
Current symptoms of peptic ulcer bleeding	
Hematemesis	25.8 (17/66)
Hematochezia	12.1 (8/66)
Melena	92.4 (61/66)
Ulcer	
Ulcer diameter*	
<1 cm	31.3 (21/67)
1-2 cm	55.2 (37/67)
>2 cm	11.9 (8/67)
Unknown	1.5 (1/67)
Ulcer location	
Stomach	25.4 (17/67)
Duodenum	74.6 (50/67)
Forrest classification	
Ia (spurting)	16.4 (11/67)
Ib (oozing)	83.6 (56/67)

Values are mean ± standard deviation or % (n/N) unless otherwise defined.

*Ulcer diameter was not available for 1 patient.

classification was the only variable significantly associated with early or late recurrent bleeding ($P = .0033$) (Table 3).

No adverse events were attributed to the use of Hemospray. In all, 6 patients (9.1% [6/66]) (Table 2) experienced 6 adverse events that required reintervention or resulted in patient morbidity or mortality (Table 4). These adverse events included 2 occurrences of perforation, 2

occurrences of chest infection/pneumonia, 1 occurrence of intestinal obstruction, and 1 occurrence of coronary artery bypass grafting because of newly diagnosed coronary artery disease. The case of GI obstruction was because of progressive adenocarcinoma in the duodenum and not because of the use of Hemospray. This lesion was not the source of bleeding treated with Hemospray. In both cases of gastric perforation, the patients received 1 application of Hemospray using 2 canisters. One case of gastric perforation was located high in the proximal body of the stomach away from the site of ulcer bleeding and was noticed during withdrawal of the endoscope after hemostasis with Hemospray was successfully achieved. Laparotomy was performed, and the perforation was stapled. The physician was unable to determine the cause of the perforation but speculated that the perforation may have been related to trauma from the endoscope. The physician assessed that the event was not directly attributed to the use of Hemospray.

Two of 66 patients died (3%), both of whom had Forrest Ia ulcers. Neither death was causally related to the use of Hemospray. The first patient had an underlying history of alcohol use with melena progressing to hematemesis with hematochezia. A Forrest Ia bleeding visible vessel was observed at the gastroesophageal junction. The attending physician did not classify this as a case of variceal bleeding. The hemorrhage was treated with Hemospray, which provided temporary control. Further visualization was obscured by a large amount of blood and clot in the stomach. Bleeding resumed at the gastroesophageal junction, and a second hemostasis was attempted with Hemospray, but the patient began vomiting. The endoscopic procedure was discontinued, the patient was intubated, and a chest x-ray demonstrated free air under the diaphragm, so the patient was referred to surgery. At surgery, there was no active bleeding at the gastroesophageal junction where the Hemospray had been deployed. However, there were engorged veins indicative of portal hypertension and cirrhosis, and a 2- to 3-cm perforation was noted midway up the lesser curvature of the stomach with significant food and gastric content contaminating the abdominal cavity. It was believed that a large ulcer obscured by the blood and clot could have already been perforated and was exacerbated by repeated emergency gastroscopies with endoscopic insufflation. A partial gastrectomy, gastrojejunostomy, and feeding jejunostomy were performed. This case is the second perforation noted in Table 4. Postoperatively, the patient developed liver failure and died.

The second patient death was a 73-year-old man who had been admitted for observation after an upper GI bleed. Two days after the initial treatment, the patient experienced hematemesis. Repeat endoscopy revealed a >2-cm Forrest Ia duodenal ulcer. Hemospray was successfully deployed, and hemostasis was achieved and maintained after observation for 5 minutes. Five hours later, the patient

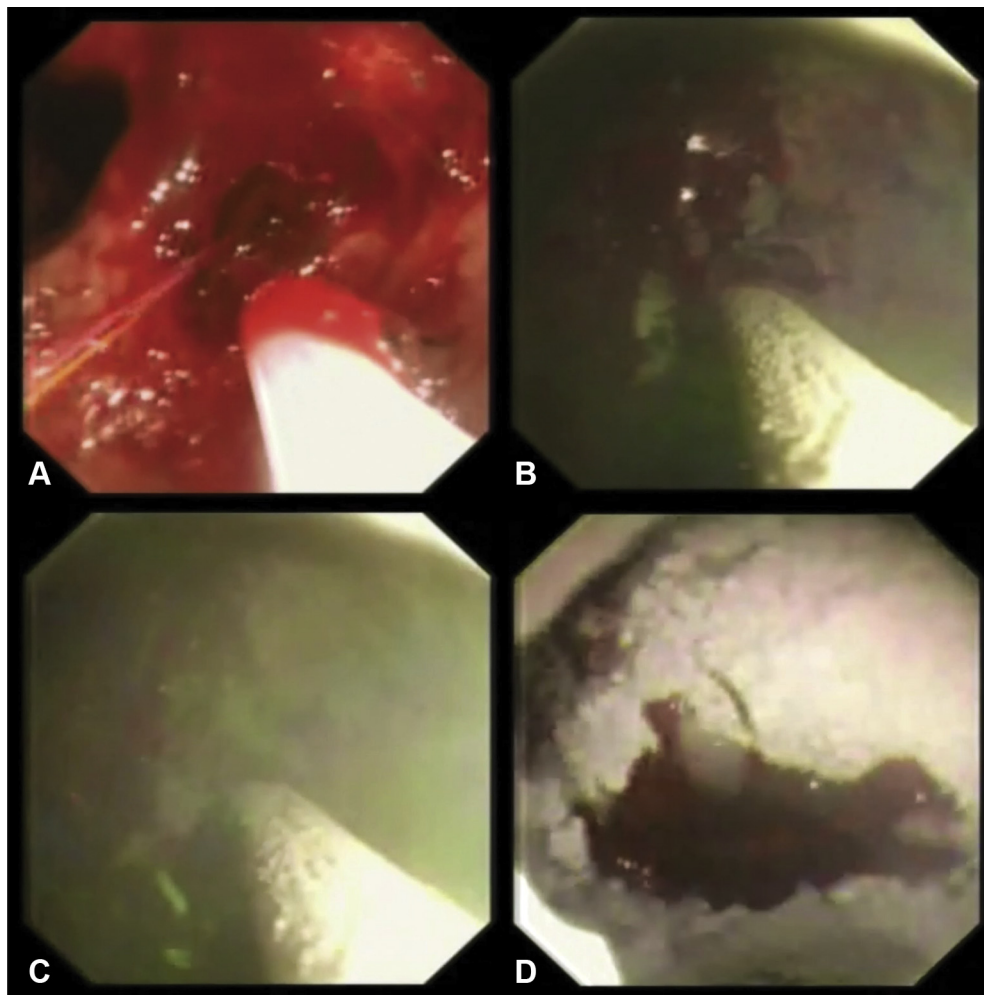


Figure 1. Treatment of a Forrest Ia ulcer with Hemospray. A Forrest Ia ulcer at the angular incisura (A) is treated with an initial application of Hemospray (B). C, Complete coverage of the bleeding site with Hemospray is achieved with an additional application. D, Oozing is observed underneath the Hemospray material before cessation of bleeding by the end of the 5-minute observational period.

TABLE 2. Hemospray outcomes by total patient population and by Forrest classification

Outcome	Total patients (n = 66)	Forrest Ia (n = 11)	Forrest Ib (n = 55)	P value
Initial hemostasis	90.9 (60)	90.9 (10)	90.9 (50)	>.99
Early (≤ 72 h) recurrent bleed	7.6 (5)	27.3 (3)	3.6 (2)	.03*
Late (>72 h) recurrent bleed	4.5 (3)	18.2 (2)	1.8 (1)	.07
Adverse events (within 30 days) [†]	9.1 (6)	27.3 (3)	5.5 (3)	.05
30-day mortality	3.0 (2)	18.2 (2)	0 (0)	.026*

Values are % (n).

*Significance by $P < .05$, Fisher exact test.

[†]Adverse events requiring reintervention or resulting in morbidity.

developed hypotension and tachycardia and was referred to surgery. During laparotomy for duodenal exclusion and gastrojejunostomy, the physician confirmed that the study ulcer at the posterior duodenal wall was the source of the recurrent arterial bleeding. Seventeen days postoperatively, the patient died of adverse events from hospital-acquired pneumonia.

DISCUSSION

A considerable body of literature describes the use of Hemospray as either a primary treatment or secondary (ie, salvage modality) treatment for nonvariceal GI bleeding. Although most reports are retrospective case series, 2 recent meta-analyses described the use of

TABLE 3. Multiple logistic regression of predictors of early or late recurrent bleeding

Variable	Odds ratio estimate	95% Confidence interval	P value
Sex			
Female vs male	1.244	.146, 10.585	.8417
Ulcer location			
Duodenum vs stomach	.197	.016, 2.424	.2045
Ulcer diameter			
0-1 cm vs >2 cm	33.428	.530, >999.999	.1577
Ulcer diameter			
1-2 cm vs >2 cm	7.756	.562, 107.073	.7780
Forrest classification			
Ia (spurting) vs Ib (oozing)	.021	.002, .274	.0033*
Hypertensive			
No vs yes	4.661	.394, 55.104	.2220

*Significance by $P < .05$, χ^2 test.

TABLE 4. Adverse events requiring reintervention or resulting in morbidity or mortality (n = 66)

Adverse event	Days after procedure	
	0-3 days	4-30 days
Perforation	2	0
Obstruction	0	1
Coronary artery bypass graft procedure for coronary artery disease	0	1
Chest infection/pneumonia	1	1
Total	3	3

Hemospray to treat patients with UGIB. Clinical outcomes included initial hemostasis in 91.0% of patients and overall rebleeding in 24.0% to 26.2% of patients.^{20,21} De Rezende et al²¹ also performed a subanalysis of 12 studies that included only patients with peptic ulcers treated with Hemospray. The initial hemostasis rate was 91.5% and overall rebleeding rate was 33.0%, with 8 adverse events.²¹ These outcomes are similar to the 90.9% initial hemostasis rate in the HALT study, although the rebleeding rate was only 13.3%. There are several possible explanations for the differences in rebleeding. First, most studies in the 2 meta-analyses were retrospective case series with a follow-up period ranging from 7 to 480 days, and many reports in the meta-analyses included a large proportion of high-risk patients and cases where Hemospray was used after failure of conventional treatment. In the HALT study, 9.1% of patients (6/66) experienced adverse events requiring reintervention or resulting in morbidity or mortality, which is higher than the number of patients who experienced adverse events in the 2 meta-analyses. The differences could also arise from different adverse event criteria used in the studies included in the meta-analyses, variations in the length of follow-up, and possible bias in case selection in retrospec-

tive series. By contrast, the prospective observational design of the HALT study tracked adverse events according to predefined criteria for the duration of the 30-day follow-up period. This study design provides a thorough determination of safety and effectiveness, which may have contributed to a higher rate of recorded adverse events.

Although previous publications on mixed peptic ulcer and non-peptic ulcer populations provide a glimpse of the “real-world” applications of Hemospray, questions remain about Hemospray’s use as a monotherapy. Lau et al²² conducted a prospective, randomized, noninferiority study of 224 patients comparing Hemospray monotherapy with conventional dual therapy. Overall, the bleeding-free probability was 89.8% with Hemospray and 81.1% with conventional therapy. Failure of initial hemostasis and rebleeding rate in patients with peptic ulcers treated with Hemospray as monotherapy were 12.5% versus 15.4% with conventional therapy, with 14 deaths in each group.²² The authors concluded that Hemospray monotherapy was noninferior to conventional dual therapy. However, the study described by Lau et al included between-group imbalances in the distribution of lesions, especially malignant bleeding that seemed to be particularly responsive to Hemospray therapy, and these data also need to be

considered in the context of the limitations of the bleeding lesion classification and related severity. Evidence suggests that Forrest Ib bleeding is associated with lower rebleeding rates compared with Forrest Ia, IIa, and IIb peptic ulcer bleeding.²³ This conclusion is supported by the HALT study data, where early rebleeding was significantly higher in patients with Forrest Ia ulcers than in patients with Forrest Ib ulcers. This realization is important because Forrest Ib ulcers formed most bleeding ulcers in the Lau et al study.²²

Few other prospective randomized studies have investigated Hemospray, and those that are available have very small sample sizes. Kwek et al²⁴ randomized 20 patients with peptic ulcers to receive either Hemospray (10 patients) or conventional treatment (10 patients). However, only 40% (8/20) had actively bleeding Forrest Ia or Ib ulcers. Of these patients, 5 patients received Hemospray (including 1 ulcer that extended into the retroperitoneum) and only 3 patients with Forrest Ia or Ib ulcers received standard dual therapy.²⁴ Hemospray requires active bleeding to achieve hemostasis and is not recommended for patients with nonbleeding vessels, so assumptions about initial hemostasis and rebleeding from this pilot study are difficult to assess.

A second pilot study of 20 patients with bleeding, malignant, upper GI ulcers randomized 10 patients to monotherapy with Hemospray and 10 patients to conventional treatment.²⁵ Initial treatment failures were crossed over to the other arm. Immediate hemostasis was achieved in 90% of patients (9/10) treated with Hemospray but only in 40% of patients (4/10) treated with conventional treatment. Treatment with Hemospray was successful in 80% of patients (4/5) who crossed over from the conventional treatment group, with an overall hemostasis rate for Hemospray-treated patients of 87.7%.²⁵ Incidence of long-term rebleeding (up to 180 days) was 20% in the Hemospray group versus 60% in the conventional treatment group,²⁵ suggesting that monotherapy with Hemospray may hold promise for treatment of patients with malignant bleeding.

Although it had a lower level of evidence than prospective randomized studies, a large prospective multicenter registry reported similar findings in 50 patients with malignant bleeding treated with Hemospray.²⁶ Hemospray was used alone in 66% of patients (33/50), and initial hemostasis was achieved in all 33 patients (100%) versus 85% of patients (11/13) when combined with conventional treatment and 75% of patients (3/4) when used as rescue therapy.²⁶ Further analysis of 202 registered patients with peptic ulcers reported rates of 88% (178/202) for initial hemostasis, 17% (26/154) for 30-day rebleeding, and 22% (38/175) for 30-day all-cause mortality.²⁷ In the registry, Hemospray was used alone, in combination with other treatments, or as a rescue therapy after conventional treatment failure. For patients treated with Hemospray alone, the immediate hemostasis rate was 88% (44/50),

rebleeding rate was 16% (5/32), and rate of 30-day all-cause mortality was 32% (12/38).²⁷ For patients treated with a combination of Hemospray and conventional methods, the immediate hemostasis rate was 89% (90/101), rebleeding rate was 15% (12/81), and rate of 30-day all-cause mortality was 16% (14/89).²⁷ Notably, immediate hemostasis was achieved in 86% of patients (44/51) who had rescue therapy after failed conventional treatments.²⁷

The HALT study data are limited by a lack of a control group for comparison. Study enrollment was hampered by the lack of actively bleeding ulcers in many of the patients screened for eligibility, because active bleeding is required for efficacy of Hemospray. The relatively small sample size limits the strength of conclusions. Finally, most patients had Forrest Ib ulcers. This is consistent with other published series on Hemospray.

Existing international guidelines recommend combination therapy (ie, injection in addition to either thermal or mechanical hemostasis techniques) for patients with peptic ulcers with stigmata that suggest a high risk of rebleeding.^{6,11,28} Until the publication of the randomized controlled trial by Lau et al,²² hemostatic powders had even been discouraged as the sole modality for peptic ulcer bleeding, with their use recommended as rescue after failure of conventional treatment or in patients with malignant bleeds or ulcers where conventional modalities are ineffective.²¹ This has changed in the new American College of Gastroenterology guidelines with the methodologic cautions expressed above.²⁹ The HALT study showed that Hemospray alone may not achieve durable hemostasis in patients with Forrest Ia spurting ulcer bleeds, although temporary hemostasis may be possible. The picture is less clear in patients with Forrest Ib ulcers. If endoscopic clips cannot be placed at the actively bleeding site or if there is risk of perforation from direct cautery, noncontact treatment with Hemospray may achieve durable hemostasis in Forrest Ib ulcers. Additionally, the use of Hemospray does not preclude the use of other treatment modalities if hemostasis is not achieved. In the current study, additional interventions allowed for end of procedure hemostasis in 66.7% of patients (4/6) where hemostasis was not achieved with Hemospray monotherapy, resulting in an overall end of procedure hemostasis rate of 97.0%. Although additional randomized trials would add clarity on the optimal use of Hemospray, the HALT study is one of the only prospective clinical studies on Hemospray monotherapy that demonstrates safety and effectiveness in achieving immediate hemostasis in patients with actively bleeding peptic ulcers.

ACKNOWLEDGMENT

We thank Nicholas D. Dey, PhD, from Cook Research Incorporated for writing and editing assistance.

REFERENCES

1. Klein A, Gralnek IM. Acute, nonvariceal upper gastrointestinal bleeding. *Curr Opin Crit Care* 2015;21:154-62.
2. Meltzer AC, Klein JC. Upper gastrointestinal bleeding: patient presentation, risk stratification, and early management. *Gastroenterol Clin North Am* 2014;43:665-75.
3. Szura M, Pasternak A. Upper non-variceal gastrointestinal bleeding—review of the effectiveness of endoscopic hemostasis methods. *World J Gastrointest Endosc* 2015;7:1088-95.
4. Fortinsky KJ, Bardou M, Barkun AN. Role of medical therapy for nonvariceal upper gastrointestinal bleeding. *Gastrointest Endosc Clin North Am* 2015;25:463-78.
5. Simon TG, Travis AC, Saltzman JR. Initial assessment and resuscitation in nonvariceal upper gastrointestinal bleeding. *Gastrointest Endosc Clin North Am* 2015;25:429-42.
6. Gralnek IM, Dumonceau JM, Kuipers EJ, et al. Diagnosis and management of nonvariceal upper gastrointestinal hemorrhage: European Society of Gastrointestinal Endoscopy (ESGE) guideline. *Endoscopy* 2015;47:a1-46.
7. Franco MC, Nakao FS, Rodrigues R, et al. Proposal of a clinical care pathway for the management of acute upper gastrointestinal bleeding. *Arq Gastroenterol* 2015;52:283-92.
8. Lu Y, Loffroy R, Lau JY, et al. Multidisciplinary management strategies for acute non-variceal upper gastrointestinal bleeding. *Br J Surg* 2014;101:e34-50.
9. Al Dhahab H, McNabb-Baltar J, Al-Taweel T, et al. State-of-the-art management of acute bleeding peptic ulcer disease. *Saudi J Gastroenterol* 2013;19:195-204.
10. Babiuc RD, Purcarea M, Sadagurschi R, et al. Use of Hemospray in the treatment of patients with acute UGIB—short review. *J Med Life* 2013;6:117-9.
11. Barkun AN, Bardou M, Kuipers EJ, et al. International consensus recommendations on the management of patients with nonvariceal upper gastrointestinal bleeding. *Ann Intern Med* 2010;152:101-13.
12. Rajala MW, Ginsberg GG. Tips and tricks on how to optimally manage patients with upper gastrointestinal bleeding. *Gastrointest Endosc Clin North Am* 2015;25:607-17.
13. Song LM, Levy MJ. Emerging endoscopic therapies for nonvariceal upper gastrointestinal bleeding. *Gastroenterol Clin North Am* 2014;43:721-37.
14. Chen YI, Barkun AN. Hemostatic powders in gastrointestinal bleeding: a systematic review. *Gastrointest Endosc Clin North Am* 2015;25:535-52.
15. Masci E, Arena M, Morandi E, et al. Upper gastrointestinal active bleeding ulcers: review of literature on the results of endoscopic techniques and our experience with Hemospray. *Scand J Gastroenterol* 2014;49:1290-5.
16. Sung JJ, Luo D, Wu JC, et al. Early clinical experience of the safety and effectiveness of Hemospray in achieving hemostasis in patients with acute peptic ulcer bleeding. *Endoscopy* 2011;43:291-5.
17. Hegade VS, Sood R, Mohammed N, et al. Modern management of acute non-variceal upper gastrointestinal bleeding. *Postgrad Med J* 2013;89:591-8.
18. Weilert F, Binmoeller KF. New endoscopic technologies and procedural advances for endoscopic hemostasis. *Clin Gastroenterol Hepatol* 2016;14:1234-44.
19. Tjwa ET, Holster IL, Kuipers EJ. Endoscopic management of nonvariceal, nonulcer upper gastrointestinal bleeding. *Gastroenterol Clin North Am* 2014;43:707-19.
20. Aziz M, Weissman S, Mehta TI, et al. Efficacy of Hemospray in non-variceal upper gastrointestinal bleeding: a systematic review with meta-analysis. *Ann Gastroenterol* 2020;33:145-54.
21. de Rezende DT, Brunaldi VO, Bernardo WM, et al. Use of hemostatic powder in treatment of upper gastrointestinal bleeding: a systematic review and meta-analysis. *Endosc Int Open* 2019;7:E1704-13.
22. Lau JY, Pittayanon R, Kwek A, et al. Non-inferiority randomized controlled trial to compare hemostatic powder Tc325 and standard therapy in bleeding from non-variceal upper gastrointestinal causes [abstract]. *Gastrointest Endosc* 2020;91:AB81.
23. Jensen DM, Eklund S, Persson T, et al. Reassessment of rebleeding risk of Forrest Ib (oozing) peptic ulcer bleeding in a large international randomized trial. *Am J Gastroenterol* 2017;112:441-6.
24. Kwek A, Ang TL, Ong PLJ, et al. Hemospray versus the combined conventional technique for endoscopic treatment of bleeding peptic ulcers: a pilot randomized controlled study [abstract]. *Gastrointest Endosc* 2016;83:AB123-4.
25. Chen YI, Wyse J, Lu Y, et al. TC-325 hemostatic powder versus current standard of care in managing malignant GI bleeding: a pilot randomized clinical trial. *Gastrointest Endosc* 2020;91:321-8.
26. Alzoubaidi D, Hussein M, Rusu R, et al. Outcomes from an international multicenter registry of patients with acute gastrointestinal bleeding undergoing endoscopic treatment with Hemospray. *Dig Endosc* 2020;32:96-105.
27. Hussein M, Alzoubaidi D, Fraile-Lopez M, et al. Hemostatic spray powder TC-325 in the primary endoscopic treatment of peptic ulcer related bleeding: multicentre international registry. *Endoscopy* 2020;53:36-43.
28. Laine L, Jensen DM. Management of patients with ulcer bleeding. *Am J Gastroenterol* 2012;107:345-60.
29. Laine L, Barkun AN, Saltzman JR, et al. ACG clinical guideline: upper gastrointestinal and ulcer bleeding. *Am J Gastroenterol* 2021;116:899-917.

SUPPLEMENTARY TABLE 1. Association of baseline patient or ulcer characteristics with early or late rebleeding in patients with initial hemostasis after Hemospray application

Variable	Patients with early or late rebleeding*		Difference of proportions	95% Confidence interval	P value
	No (n = 52)	Yes (n = 8)			
Sex					
Female	30.8 (16)	25.0 (2)	5.77	(-26.75, 38.29)	>.99
Male	69.2 (36)	75.0 (6)	-5.77	(-38.29, 26.75)	
Location of ulcer					
Duodenum	76.9 (40)	87.5 (7)	-10.58	(-36.20, 15.04)	.67
Stomach	23.1 (12)	12.5 (1)	10.58	(-15.04, 36.20)	
Ulcer diameter					
0-1 cm	30.8 (16)	25.0 (2)	5.77	(-26.75, 38.29)	.47
1-2 cm	59.6 (31)	50.0 (4)	9.62	(-27.51, 46.74)	
>2 cm	9.6 (5)	25.0 (2)	-15.38	(-46.44, 15.67)	
Forrest classification					
Ia (spurting)	9.6 (5)	62.5 (5)	-52.88	(-87.38, -18.39)	.002†
Ib (oozing)	90.4 (47)	37.5 (3)	52.88	(18.39, 87.38)	
More than 1 site of bleeding					
No	92.3 (48)	100 (8)	-7.69	(-14.93, -0.45)	>.99
Yes	7.7 (4)	0 (0)	7.69	(.45, 14.93)	
Hypertension					
No	55.8 (29)	50.0 (4)	5.77	(-31.42, 42.95)	>.99
Yes	44.2 (23)	50.0 (4)	-5.77	(-42.95, 31.42)	
Diabetes					
No	75.0 (39)	87.5 (7)	-12.50	(-38.26, 13.26)	.67
Yes	25.0 (13)	12.5 (1)	12.50	(-13.26, 38.26)	

*Values are % (n).

†Significance by $P < .05$, Fisher exact test.